

Value of 3D Ultrasound in the Management of Suspected Asherman's Syndrome

Jaime Knopman, M.D., and Alan B. Copperman, M.D.

OBJECTIVE: To assess the value of 3-dimensional (3D) ultrasound in the management of patients with suspected Asherman's syndrome.

STUDY DESIGN: A case series of 54 infertile patients who presented to a tertiary care center between 1998 and 2004 with suspected Asherman's syndrome underwent both hysterosalpingography and 3D ultrasound prior to hysteroscopy. Sensitivity and the ability to attain fertility postoperatively were calculated.

RESULTS: Intrauterine adhesions (IUAs) were demonstrated on 3D ultrasound and HSG in all cases and confirmed by hysteroscopy. However, 3D ultrasound had a sensitivity of 100% and HSG a sensitivity of 66.7% for correctly grading the extent of IUAs. In 61.1% of cases in which HSG results were inconsistent with hysteroscopy, lower uterine segment outflow obstruction was present, and HSG misclassified findings as severe Asherman's with complete cavity obstruction. Postoperatively, 90% of patients conceived.

CONCLUSION: 3D ultrasound provides a more accurate depiction of adhesions and extent of cavity damage

than HSG in patients with suspected Asherman's syndrome, particularly when differentiating severe IUAs from lower uterine segment outflow obstruction. There-

fore, grading systems utilizing HSG to classify severity of disease should be revised to include 3D ultrasound findings. (J Reprod Med 2007; 52:1016-1022)

3D ultrasound provides a more accurate depiction of adhesions and extent of cavity damage than HSG in patients with suspected Asherman's syndrome....

Keywords: Asherman syndrome; infertility, female; pregnancy outcome; three-dimensional image;

ultrasonography.

Asherman's syndrome is defined as the presence of intrauterine adhesions either partially or completely obliterating the uterine cavity. Although a relatively uncommon diagnosis in the general population, it is often cited as the etiology of pregnancy complications in the infertile population.¹ It most often develops after dilation and curettage (D&C) of a recently pregnant uterus; however, it can also develop following the secondary removal of placental remnants or postpartum hemorrhage or, in fact, after any intrauterine manipulation. Clinical

From the Division of Reproductive Endocrinology and Infertility, Department of Obstetrics and Gynecology, Mt. Sinai School of Medicine, New York, New York.

This research was presented in the form of a poster presentation at the 61st Annual Meeting of the American Society for Reproductive Medicine, Montreal, Quebec, Canada, October 16-19, 2005.

Address correspondence to: Alan B. Copperman, M.D., Reproductive Medicine Associates of New York, 635 Madison Avenue, 10th Floor, New York, NY 10022 (acopperman@rmany.com).

Financial Disclosure: The authors have no connection to any companies or products mentioned in this article.

symptoms associated with the syndrome include menstrual abnormalities, such as hypomenorrhea or amenorrhea, pelvic pain, infertility and recurrent pregnancy loss.² The extent of intrauterine adhesions (IUAs) is graded and the severity of disease classified by extent of cavity obliterated, location of

Grading systems utilizing HSG to classify the severity of disease should be revised to include 3D ultrasound findings.

adhesions within the cavity and character of the adhesions.³

The diagnosis of IUAs has been traditionally limited to hysterosalpingography (HSG), a simple, safe, inexpensive, sensitive and minimally invasive procedure that allows visualization of the uterine cavity. Furthermore, it provides information regarding tubal patency.^{4,5} However, since it is an indirect means of demonstrating the uterine cavity as well as the type, extent and exact location of filling defects, the results are often nonspecific.⁴ In addition, another potential drawback of HSG is its inability to characterize the uterine cavity beyond where radiopaque contrast perfuses. Specifically, in cases of lower segment outflow tract obstruction, limited information can be derived from HSG (Figure 1). Therefore, hysteroscopy, which allows direct visualization of the entire cavity in addition to the ability to biopsy lesions and lyse adhesions, is considered the gold standard for the diagnosis and treatment of IUAs.^{4,7} Despite its limitations, HSG remains the initial screening tool for detecting IUAs, and when intrauterine abnormalities are demonstrated, therapeutic hysteroscopic resection of synechiae may be clinically indicated.⁸

While investigators have studied the diagnostic accuracy of transvaginal ultrasound (TVS), the machines utilized were, in most cases, 2D.^{6,7,9-12} Use of 3D sonography, which allows interactive visualization through multiplanar reformatting, can provide a more accurate assessment. Therefore, we propose that use of 3D ultrasonography in patients with Asherman's syndrome will improve both diagnostic and prognostic capabilities when compared to the traditional HSG. The derived images produced by the 3D machine are more consistent with the location of the lesions and the percent of cavity ob-

structed; that ultimately correlates more closely with prognosis (Figure 2). This study was conducted to assess the value of 3D ultrasound in the management of patients with suspected Asherman's syndrome.

Materials and Methods

In this case series, from 1998 to 2004, 54 women were identified during evaluations for secondary infertility as having Asherman's syndrome. All patients were seen at an academic reproductive medicine practice by the same reproductive endocrinologist and were routinely evaluated with 3D ultrasound, HSG and hysteroscopy. Extent of cavity damage and severity of disease were defined by the March grading system.³ In this system, adhesions are judged to be severe if more than three fourths of the uterine cavity is obliterated, agglutination of the uterine walls or thick bands are present, or the ostial areas and upper cavity are occluded. Adhesions are considered moderate if one fourth to three fourths is involved, no agglutination of the uterine walls is present, and ostial areas and the upper fundus is only partially involved. Adhesions are considered minimal if less than one fourth of the uterus is scarred, adhesions are thin or filmy, and ostial areas and the upper fundus are minimally involved or clear.³

In addition to 3D ultrasound, patients underwent a thorough infertility investigation, composed of documentation of ovulation, analysis of semen, baseline ovarian reserve testing and HSG. Preoperative sonographic evaluation included traditional 2D sagittal endometrial thickness, 3D routine acquisition (collection of anatomy as 3D volume data), multiplanar display (simultaneous visualization of 3 orthogonal scan planes—longitudinal, transverse and a unique "horizontal" plane—which often provides views of anatomy often not attainable using 2D ultrasound imaging) and volume rendering (use of computer rendering to create at 3D ultrasound image). For the purpose of standardization, all patients were evaluated, imaged and operated on by the same physician. HSG was performed in standard fashion by placing a catheter tip within the external cervical os and injecting radiopaque oil-contrast material into the uterine lumen. All films were reviewed and interpreted by 1 physician. For patients who cycled, the HSG was scheduled in the proliferative phase of the menstrual cycle. Following the preoperative HSG and 3D ultrasound, appropriate candidates were scheduled

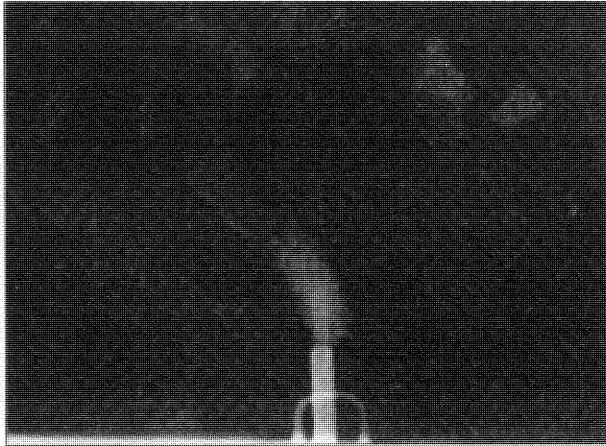


Figure 1 Hysterosalpingogram revealing lower segment obstruction. Note that it is not possible to evaluate the uterine cavity superior to the blockage.

for operative hysteroscopy. At the time of hysteroscopy, percentage of cavity obstructed, presence of outflow obstruction and severity of Asherman's syndrome were evaluated. Laparoscopy was performed in 18/54 (33%) of patients at the discretion of the treating physician. Indications included suspicion of concomitant intraperitoneal pathology and high risk of uterine perforation.

The intraoperative technique included careful dilatation of the cervix and insertion of a 10-mm resectoscope. Precise, targeted resection of IUAs was performed. When there were isolated islands of endometrium, attempts were made to connect them. In all cases, attempts were made to restore the normal uterine anatomy with a minimum of cautery and trauma. No curettage was performed. Postoperatively, a no. 8 pediatric Foley catheter was transcervically inserted into the uterus, and the balloon was expanded with 2 mL of saline. In addition, conjugated estrogen (2 mg by mouth twice daily) and doxycycline (100 mg by mouth twice daily) were administered for at least 10 days to all patients. In all cases, the Foley catheter either spontaneously fell out or was removed within 14 days. (All remained in place at least 48 hours.)

Postoperative 3D sonograms were performed on all patients at their postoperative follow-up. The percent cavity obstructed and endometrial thickness (following 2 weeks of postoperative estrogen therapy) were evaluated at the time of this procedure. The results of the hysteroscopy were compared to the results of both the 3D sonogram and

the HSG to evaluate each procedure's diagnostic accuracy.

For statistical analysis, the sensitivity of HSG and 3D ultrasound for identifying the presence and severity of IUAs as well as outflow obstruction were calculated using hysteroscopy as the gold standard. Pregnancy rates and live birth data were also collected for all patients. Informed consent was obtained for all surgical procedures.

Results

The patients ranged in age from 26 to 49 years, with a mean age of 35.8. Fifty-three (98.15%) had secondary infertility (1 with amenorrhea only) and presented with a medical history and clinical symptoms suggestive of Asherman's syndrome/IUAs as the etiology of their reproductive problems. Seven of 54 (12.96%) patients presented with hypomenorrhea and 12 of 54 (22.22%) with amenorrhea. All patients had a history of antecedent intrauterine trauma preceding their presentation (Table I).

On preoperative HSG, 22/54 (40.74%) patients presented with cavities that were $\leq 30\%$ obstructed (mild), 10/54 (18.52%) had cavities that were $> 30\%$ but $\leq 60\%$ obstructed (moderate), and 22/54 (40.74%) had cavities that were $> 60\%$ obstructed (severe). On 3D ultrasound, 30/54 (55.56%) patients had cavities that were $\leq 30\%$ obstructed (mild), 18/54 (33.33%) had cavities that $> 30\%$ but $\leq 60\%$ obstructed (moderate), and 6/54 (11.11%) had cavities that were $> 60\%$ obstructed (severe) (Table II).

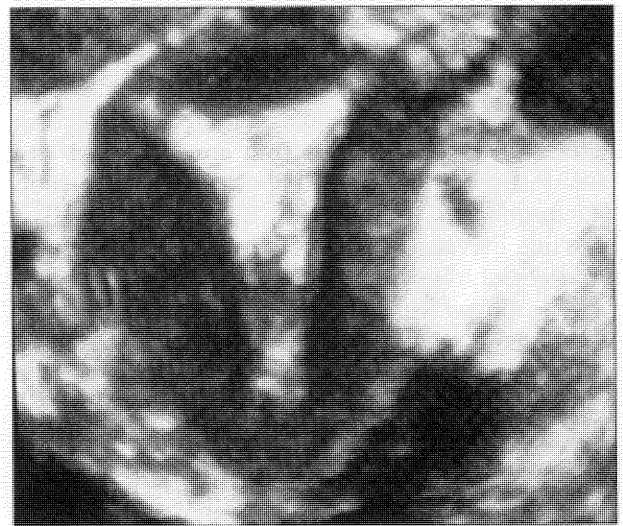


Figure 2 3D sonogram of the patient in Figure 1. Note the normal contour of the uterus above the obstruction.

Table I Etiology of IUAs

Antecedent intrauterine trauma	No. of patients	% Of patients
1 D&C/D&E	22	38.89
2 D&Cs/D&Es	15	24.07
3 D&Cs/D&Es	6	11.11
4 or more D&Cs/D&Es	4	7.41
1 Myomectomy	1	1.85
2 Myomectomies	1	1.85
1 C/S	2	3.70
1 Myomectomy & 1 C/S	1	1.85
2 Myomectomies & 1 C/S	1	1.85
Prior hysteroscopy	1	1.85

N=54.

D&C = dilation and curettage, D&E = dilation and evacuation, C/S = cesarean section.

Laparoscopy was performed on 18/54 (33.33%) patients, and perforations occurred in 2/18 (3.70%) cases. (Both occurred in patients who underwent laparoscopy concomitant with hysteroscopy.)

In 54/54 (100%) of patients the extent of cavity obstruction and location of lesions found during hysteroscopy was consistent (defined in this study as less than a 20% discrepancy in detection of percentage of cavity obstructed) with their preoperative 3D ultrasound findings, while the preoperative results of the HSG were consistent in 36/54 (66.67%) patients. In the 18/54 (33.33%) cases in which hysteroscopy was consistent with 3D ultrasound but not HSG, 11/18 (61.11%) had evidence of lower uterine segment outflow obstruction. (In total, 13 patients demonstrated lower uterine segment obstruction on hysteroscopy.) In these 11 patients, the preoperative 3D ultrasound correctly differentiated between complete cavity obliteration

and lower segment outflow obstruction. In the 7/18 (38.89%) patients who did not have evidence of outflow obstruction but had preoperative HSGs that were inconsistent with hysteroscopy, 7/7 (100%) of the HSGs incorrectly overgraded the severity of intracavitary adhesive disease.

Postoperatively, the balloon catheter remained in place for at least 10 days in 46/54 (85.19%) patients. In 48/54 (88.89%) patients, the postoperative cavity was designated adequate to attempt conception (<20% of obstruction remaining as seen on 3D ultrasound, following 1 operative procedure). The remaining 6/54 (11.11%) required additional lysis of adhesions prior to attaining a cavity adequate to attempt conception. Results of sonographic assessment of endometrial thickness are given in Table III.

A pregnancy rate of 45/50 (90%) was achieved in patients who desired fertility; 3/54 (5.56%) did not desire fertility, and 1/54 (1.85%) were lost to follow-up. Of those pregnancies, 19/45 (42.22%) were spontaneous, 8/45 (17.78%) were achieved with injectable gonadotropins and intrauterine insemination, and 18/45 (40%) were achieved with in vitro fertilization/ovum donation. The live birth rate was 35/50 (70%). Neither etiology of Asherman's syndrome nor number of prior D&Cs predicted outcome.

Discussion

There are numerous modalities employed to diagnose and classify Asherman's syndrome. Common protocols include use of HSG,^{4-6,8,9,13,14} MRI,¹⁵⁻¹⁷ sonohysterography^{6,10-12} and transvaginal ultrasound (both 2D^{6,9-12,18} and 3D^{11,18-20}). The most widely studied and utilized in current practice is HSG. Its high sensitivity, which has been reproduced in numerous large-scale studies, has tradi-

Table II Comparison of Classification of Severity Detected by HSG and 3D Sonography Preoperatively vs. Hysteroscopy (Gold Standard)

IUAs	No. of patients with IUAs detected with HSG	% Of patients with IUAs detected with HSG	No. of patients with IUAs detected with 3D sonography	% Of patients with IUAs detected with 3D sonography	No. of patients with IUAs detected with hysteroscopy	% Of patients with IUAs detected with hysteroscopy
Presence of adhesions	54	100	54	100	54	100
Mild (<30% obstructed)	22	40.74	30	55.56	30	55.56
Moderate (30-60% obstructed)	10	18.52	18	33.33	18	33.33
Severe (>60% obstructed)	22	40.74	6	11.11	6	11.11
Lower segment outflow obstruction	2	15.38	13	100	13	100

Table III Preoperative/Postoperative Endometrial Thickness on 3D Ultrasound

Preoperative endometrial lining	No. of patients	% Of patients	Postoperative endometrial lining	No. of patients	% Of patients
≤5 mm	18	33.33	≤5 mm	1	1.85
>5 mm but ≤7 mm	23	42.59	>5 mm but ≤7 mm	4	7.41
>7 mm	13	24.07	>7 mm	49	90.75

N=54.

tionally made it the preferred mechanism for screening patients with suspected IUAs. However, many studies have shown that HSG produces a large number of false positive results, specifically in those whose cavities contain lesions other than IUAs, such as cervical stenosis, endometrial polyps and myomas.^{4,11} Furthermore, as the image produced by HSG is determined by contrast perfusion, the ability to evaluate the entire cavity and accurately assess the grade of disease is limited, notably in patients with adhesions in the lower uterine segment. Even in cavities with <10% of scar tissue, the presence of adhesions in the lower segment will limit contrast perfusion and affect the quality of the HSG and assessment of the severity of disease. Therefore, patients with basically normal cavities (<10% scar tissue) but the presence of adhesions in the lower segment will have HSGs similar to those in patients with severe disease (>50%), and their disease classification and thus management of disease will be incorrect (Figures 3 and 4). In addition, even in cases without lower tract obstruction, HSG overgraded the severity of adhesions in this study due to decreased clarity in comparison to 3D ultrasound. Additional imaging could assist the surgeon

by preoperatively presenting a more precise map of the intrauterine pathology.

Sonohysterography (SHG) has been studied for its utility in identifying IUAs; however, despite a few small studies and case reports^{6,10,21} that demonstrated diagnostic accuracy superior to that of HSG, a larger study concluded that both 2D SHG and HSG have similar sensitivity with high false positive rates.¹¹ It has been proposed that adding 3D imaging to SHG may improve these results.¹¹ Conventional 2D TVS has also been utilized, but because conflicting data has been produced, its efficacy in diagnosing and prognosticating Asherman's remains questionable.^{6,7,9} While Fedele et al and Shalev et al demonstrated, in small series, the ability to achieve useful information with 2D TVS, these results have been difficult to reproduce.^{7,9} In fact, in a series published by Soares et al, 2D TVS failed to detect IUAs in any of the 4 cases studied and gave 3 false positive diagnoses.⁶ Sylvestre et al also looked at the efficacy of 2D ultrasound (in a series of 209 patients) and showed a sensitivity of 97% and specificity of 11%, suggesting that while 2D ultrasound can be an effective screening test, there are a large number of false positive IUA results, most com-

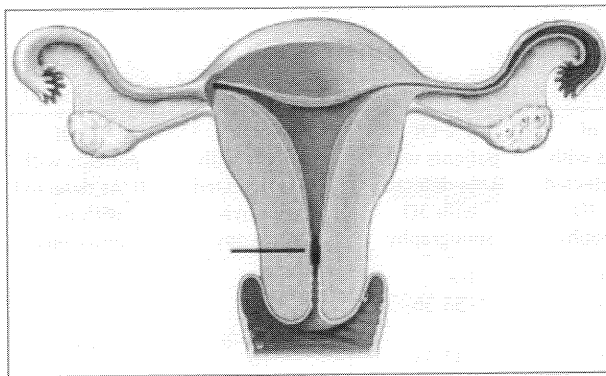


Figure 3 Frontal plane demonstrating a cavity with <10% scarring. Normal cavity with outflow obstruction.

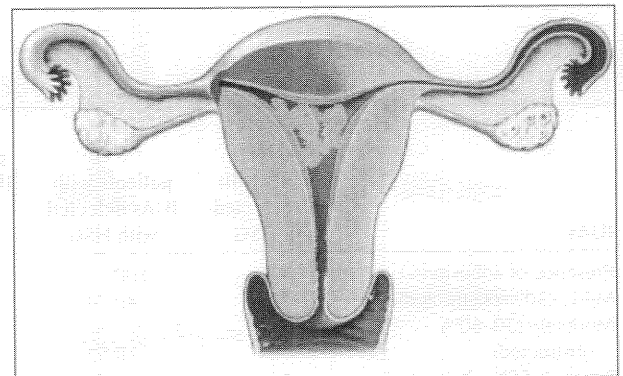


Figure 4 Frontal plane demonstrating about 50% of cavity scarred. Abnormal cavity without outflow obstruction.

monly with respect to polyps, myomas, cervical stenosis and müllerian abnormalities.¹¹ Therefore, 2D ultrasound does not appear to offer a more accurate diagnostic modality than HSG.⁴

There are limited studies in English comparing the diagnostic and prognostic capabilities of 3D ultrasound to those of other modalities. In 1 study, Sylvestre et al showed an increase in specificity for 3D ultrasound (45%) vs. 2D ultrasound (11%) in the demonstration of intrauterine lesions.¹¹ They concluded that the addition of the coronal plane was responsible for the gain in accuracy.¹¹ The only comparable modality, MRI, has shown promise in some case reports, but at a tremendous increase in imaging time and cost.¹⁵⁻¹⁷

In this study, we evaluated the ability of 3D ultrasound not only to identify the presence of adhesions but also to correctly classify the severity of disease, most notably with respect to percentage of cavity obstructed and lower tract obstruction. We demonstrated that 3D ultrasound had higher sensitivity than HSG in correctly assessing the grade of cavity adhesion and differentiating lower tract obstruction from severe cavity disease. Therefore, as prognosis in Asherman's patients is based on severity of disease, it appears from our data that 3D ultrasound more accurately assesses prognosis. Furthermore, we suggest that because data obtained from 3D ultrasound correlates more closely with the character and extent of disease, it could be a helpful tool in predicting fertility outcome postoperatively. We attribute a great deal of our high pregnancy rates to the preoperative information obtained by 3D ultrasound because its visual images allowed us to perform a more thorough procedure, which ultimately resulted in better treatment and higher success rates. Therefore, we propose that a clearer preoperative visual picture, such as that provided by 3D ultrasound, assists in intraoperative visual capabilities and that is, combined with good surgical technique and postoperative care, leads to successful reproductive outcomes.

As a case series with a single, nonblinded operator and interpreter, this study was limited. The operator was cognizant of the participant's preoperative HSG and 3D ultrasound results prior to performing hysteroscopy. This knowledge could have biased his intraoperative assessment. Therefore, the sensitivity values, which favor 3D ultrasound as more consistent with the hysteroscopic findings, could be flawed due to operator bias. Thus, to fully assess the utility of 3D ultrasound in

the management of Asherman's, a blinded study in which the operator is unaware of the results of the patient's preoperative studies could be performed. Unfortunately, this would limit his/her abilities to utilize the information gathered from the sonographic assessment and thus compromise the surgical procedure. In addition, because the same operator performed all the surgical procedures, it is possible that his surgical skills improved greatly, possibly making him more adept at correlating the imaging findings with the surgical findings.

In summary, this study was the first to demonstrate the benefit of 3D ultrasound over HSG in the management of Asherman's syndrome. 3D ultrasound provides a more accurate depiction of adhesions and extent of cavity damage than HSG in patients with suspected Asherman's syndrome, particularly when differentiating severe IUAs from lower uterine segment outflow obstruction. Therefore, grading systems utilizing HSG to classify the severity of disease should be revised to include 3D ultrasound findings.

References

1. Al-Inany H: Intrauterine adhesions: An update. *Acta Obstet Gynecol Scand* 2001;80:986-993
2. Magos A: Hysteroscopic treatment of asherman's syndrome. *Reprod BioMed Online* 2002;4:46-51
3. March CM, Israel R, March AD: Hysteroscopic management of intrauterine adhesions. *Am J Obstet Gynecol* 1978;130:653-665
4. Preutthipan S, Linasmita V: A prospective comparative study between hysterosalpingography and hysteroscopy in the detection of intrauterine pathology in patients with infertility. *J Obstet Gynaecol Res* 2003;29:33-37
5. Snoweden E, Jarrett J, Dawood M: Comparison of diagnostic accuracy of laparoscopy, hysteroscopy, and hysterosalpingography in evaluation of female infertility. *Fertil Steril* 1984;41:709-713
6. Soares S, Reis M, Camargos A: Diagnostic accuracy of sonohysterography, transvaginal sonography, and hysterosalpingography in patients with uterine cavity diseases. *Fertil Steril* 2000;73:406-411
7. Shalev J, Meizner I, Bar-Hava I, et al: Predictive value of transvaginal sonography performed before routine diagnostic hysteroscopy for evaluation of infertility. *Fertil Steril* 2000;73:412-417
8. Valle R, Sciarra J: Intrauterine adhesions: Hysteroscopic diagnosis, classification, treatment, and reproductive outcome. *Am J Obstet Gynecol* 1988;158:1459-1470
9. Fedele L, Bianchi S, Dorta M, et al: Intrauterine adhesions: Detection with transvaginal ultrasound. *Radiology* 1996;199:757-759

10. Salle B, Gaucherand P, Hilaire P, et al: Transvaginal sonohysterographic evaluation of intratuterine adhesions. *J Clin Ultrasound* 1999;27:131-134
11. Sylvestre C, Child T, Tulandi T, et al: A prospective study to evaluate the efficacy of two- and three-dimensional sonohysterography in women with intrauterine lesions. *Fertil Steril* 2003;79:1222-1225
12. Bonilla-Musoles F, Raga F, Blanes J, et al: Three-dimensional hysterosonographic evaluation of the normal endometrium: Comparison with transvaginal sonography and three-dimensional ultrasound. *J Gynecol Surg* 1997;13:101-107
13. Wang CW, Lee CL, Lai YM, et al: Comparison of hysterosalpingography and hysteroscopy in female infertility. *J Am Assoc Gynecol Laprosc* 1996;3:581-584
14. Dalfo A, Ubeda B, Ubeda A, et al: Diagnostic value of hysterosalpingography in the detection of intrauterine abnormalities: A comparison with hysteroscopy. *AJR Am J Roentgenol* 2004;183:1405-1409
15. Bacelar AC, Wilcock D, Powel M, et al: The value of MRI in the assessment of traumatic intra-uterine adhesions (Asherman's syndrome). *Clin Radiol* 1995;50:80-83
16. Letterie GS, Haggerty MF: Magnetic resonance imaging of intrauterine adhesions. *Am J Obstet Gynecol* 1994;171:102-106
17. Dueholm MD, Lundorf E, Hansen E, et al: Evaluation of the uterine cavity with magnetic resonance imaging, transvaginal sonography, hysterosonographic examination, and diagnostic hysteroscopy. *Fertil Steril* 2001;76:350-357
18. La Torre R, De Felice C, De Angelis C, et al: Transvaginal sonographic evaluation of endometrial polyps: A comparison with two dimensional and three-dimensional contrast sonography. *Clin Exp Obstet Gynecol* 1999;26:171-173
19. Radonic E, Funduk-Kurjak B: Three-dimensional ultrasound for routine check-up in in vitro fertilization patients. *Croat Med J* 2000;41:262-265
20. Pal A, Babinszki A, Vajda G, et al: Diagnosis of Asherman's syndrome with three-dimensional ultrasound. *Ultrasound Obstet Gynecol* 2000;15:341-342
21. Widrich T, Bradely LD, Mitchinson AR, et al: Comparison of saline infusion sonography with office hysteroscopy for the evaluation of the endometrium. *Am J Obstet Gynecol* 1996;174:1327-1334
22. Orhue AAE, Aziken ME, Igbefoh JO: A comparison of two adjunctive treatments for intrauterine adhesions following lysis. *Int J Gynecol Obstet* 2003;82:49-56